DOI: 10.56511/JIPBS.2015.v2.i04.pp522-536

Journal of Innovations in Pharmaceuticals and Biological Sciences
www.jipbs.com

JIPBS

ISSN: 2349-2759

Research article

Leaves extracts of *Gongronema Latifolium* and *Ocimum Gratissimum* offer synergy on organ weights alleviation and pancreatic resurgence against Streptozotocin diabetic rats

Usoh, Itoro Friday*, Akpanyuyng, Edet Okon

Department of Biochemistry, Faculty of Basic Medical Sciences, University of Uyo, Nigeria.

Abstract

This study unveiled the pancreatic regenerative capacity and organs weight alleviation of combined leaves extracts of *Gongronema latifolium* (GL) and *Ocimum gratissimum* (OG) against streptozotocin-induced diabetic rats. Thirty-six male albino rats were divided into 6 groups of 6 rats each. Groups A and F received placebo treatment and served as diabetic and normal controls respectively, B, C and D respectively received 200mg/kg b.w GL and OG and 100mg/kg b.w. each of combined GLOG. and E received 5 IU/kg b.w insulin (subcutaneously). During 28 days of treatment, daily changes in blood glucose were measured. After this period, animals were sacrificed and organs viz: liver, pancreas, kidney and heart collected and weighed. Serum was collected for alpha-amylase analysis. From the results, the extracts significantly ($p<0.05$) attenuated STZ elevation in percentage blood glucose concentrations by decreasing their levels. There was significant ($P<0.05$) increase in relative organ weights of diabetic control rats compared to normal control and treated rats. The combined extracts treated animals exhibited significant ($P<0.05$) decrease in relative organ weights as compared to single extracts treated groups. The activity of serum alpha amylase decreased (380.08±0.34) significantly in diabetic control when compared to normal control and all treatment groups. In combined extracts treated rats, its activity decreased (438.44±0.47) significantly ($p<0.05$) when compared to single extracts treated rats, hence displaying synergy. The histology of pancreas of extract treated animals reversed the pancreatic lesions observed in diabetic control rats. Comparatively, the combined extracts displayed a significant synergistic pancreatic resuscitating effect than single extracts.

Key words: *Gongronema latifolium, Ocimum gratissimum,* Streptozotocin, Pancreas, diabetes, rats

***Corresponding Author: Usoh, Itoro Friday,** Department of Biochemistry, Faculty of Basic Medical Sciences, University of Uyo, PMB 1017, Uyo, Nigeria.

1. Introduction

Diabetes mellitus (DM) is a major health problem globally [1, 2]. It is a complex metabolic disease caused by impairment of insulin signalling pathways and usually results from pancreatic β-cells deficiency and/ or a deficiency of insulin. The total

©JIPBS, All rights reserved

number of people with diabetes is projected to rise from 171 million in 2000 to 366 million in 2030 [3]. Diabetes mellitus type-I is an autoimmune disorder caused by lymphocytic infiltration and β-cells destruction within the pancreatic islets of Langerhan. The pancreatic β-cells are lost in number and volume, leading to severe permanent insulin deficiency [4]. Insulin is a polypeptide hormone produced by the beta cells of the islet of Langerhan (endocrine pancreas) with a general anabolic effect on fuel metabolism in tissues. Diabetes can lead to complications such as hypoglycemia, diabetic ketoacidosis or non-ketotic hyperosmolar coma. More serious complications associated with long term diabetes include cardiovascular diseases, chronic renal failure, renal damage and neuropathy with damage to extremities. There are several evidences that demonstrate that diabetic complications are closely associated with oxidative stress persuaded by free radicals generation [5]. Streptozotocin is used to induce diabetes. The chemistry of STZ describes a glucose moiety with a highly reactive nitrosourea side chain. The glucose moiety directs it uptake by pancreatic beta cells with ease, via binding to a membrane receptor, identified to be the glucose transporter 2 (GLUT 2) [6]. There is a reported high affinity of STZ for the β-cell membrane [7]. The nitrosourea side chain on the other hand is thought to initiate its cytotoxic action. The mechanism of action of STZ to induce diabetes is its selective toxicity to pancreatic β-cells via alkylation of DNA [8], generation of NO and free radicals [9]. According to [10] the potent alkylating property of STZ is the major reason of its toxicity, although the synergistic action of both NO and ROS may also contribute to DNA fragmentation and other deleterious changes caused by STZ.

Pancreatic transplantation therapies for DM include whole organ transplantation [11], transplantation of isolated islets [12,13] and regeneration therapy [14]. The transplantation of both a whole organ and isolated islets has been successfully used in the clinical treatment of type 1 DM as it is reported to improve the quality of life, prevent or slow the developments of microvascular or macrovascular abnormalities [15-18]. It is considered a viable option for diabetic patients with end stage renal disease who must undergo kidney transplant. However, pancreatic transplantation alone in a patient with diabetes mellitus remains controversial because the disadvantages of exogenous insulin therapy are replaced with risks of the transplantation procedure itself and the complications of immunosuppressive medications [19]. Moreover, a shortage of donors and the quality of a donor's pancreas limits the widespread use of this treatment modality [20]. Cure for diabetes defies physicians and many victims cannot meet the cost of conventional drugs. Therefore, it has become imperative to investigate alternative sources of medicament, especially those that are cheap and easily sourced. Population increase, inadequate drug supply, exorbitant cost of treatment and side effects of several conventional drugs have increased the dependence on plant materials as source of medicine for a variety of ailments, many of which are yet to be scientifically validated [21]. The use of various plant extracts and herbal biomolecules has been reported to possess hypoglycemic effects, cause a regeneration of pancreatic islets, ameliorate diabetes and lessen its complications [22-25]. *Gongronema*

latifolium Benth belongs to the domain: Eukaryota (Eukaryotes). It belongs to the class, subclass, family, genus and species of magnoliopsida (dicotyledons), lamiidae, Asclepiadaceaae, *Gongronema* and *latifolium*-Benth respectively. *Gongronema latifolium* is commonly called Utazi in the south eastern and Arokeke in the south western parts of Nigeria. It is used as vegetable in the preparation of many African dishes. In traditional folk medicine, the leaf is used for treatment of diabetes and hypertension as well as for treatment of typhoid fever [26]. It is also used to dispel stomach upset and pains and to enhance the return of menstrual cycle. *Gongronema latifolium* is primarily used as a staple vegetable/spice by some African cultures to help support the pancreas [27]. The hypoglycaemic and antihyperglycaemic properties of the ethanolic stem extract of *Gongronema latifolium* have been articulated in a review by [28]. Furthermore, literature is available on the haematological changes following oral administration of ethanolic root extract of *Gongronema latifolium* [29]. Also available is the effect of long term consumption of a diet supplemented with leaves of *Gongronema latifolium* on serum protein, haemoglobin, cholesterol, lipid peroxidation, white blood cells, antioxidant enzymes such as glutathione-s-transferase, superoxide dismutase, and liver function enzymes namely alanine transaminase, aspartate transaminase and alkaline phosphatase [30]. *Ocimum gratissimum* (Labiatae), popularly known as popularly known as "scent leaf" is a native of Africa and Asia but is now distributed to other parts of the World including the United States of America [31]. The plant is used in Nigeria by traditional medicine practitioners for the treatment of various diseases including epilepsy, diarrhoea, mental illness and fever [32]. The leaf extract of O. *gratissimum* is reportedly shown to contain potent bioactive components (essential oils) [31, 33].

A combination of herbs or phytochemicals from more than one source has proved more useful and beneficial in management of various ailments because the combined secondary metabolites synergistically potentiate biological effects with minimum side effects [34]. In view of this, we investigated the synergistic resuscitating effect of ethanolic leaves extracts of *Gongronema latifolium* and *Ocimum gratissimum* on the pancreas and body and organ weights of streptozotocin-induced diabetic rats.

2. Materials and Methods

Collection and Preparation of Plant Materials

Fresh but matured leaves of *Gongronema latifolium* and *Ocimum gratissimum* were collected from Atimbo, Akpabuyo Local Government Area of Cross River State. They were both identified and authenticated in the Department of Botany, University of Calabar, Calabar. 500g each of *Gongronema latifolium* and *Ocimum gratissimum* were thoroughly washed with clean tap water to remove dust particles and debris and shade dried. The dried plant materials were separately ground into powder with KENWOOD electric blender (KENWOOD LTD. ENGLAND). The powdered samples were each soaked in 80% ethanol and kept in a glass container with a plastic screwed cap and kept in a refegirator for 48 hours at 4°C. They were filtered using a cheese material and afterwards WhatMan No.1 filter paper. The filtrates were separately concentrated *invacuo* at 37-40°C using a rotary evaporator. The concentrates were

allowed open in a water bath (40°C) for complete ethanol removal. The dried extracts were refrigerated at 2-8°C until required for use. The concentration of the extract was determined by drying a known volume and measuring the dry weight.

Experimental Animals

Thirty-six (36) male albino rats of Wistar strain weighing between 164-258g were obtained from the animal house of the College of Health Sciences University of Calabar. The animals were allowed to acclimatize for two weeks in the Biochemistry departmental animal house facility, University of Calabar where experiment was carried out. The animals were housed in well ventilated cages (wooden bottom and wire mesh top) where bedding was replaced every two days, and kept under controlled environmental conditions (room temperature of about 27°C and 12 hour light/dark cycle). The animals were fed with growers marsh and water from tap *ad libitum*. The animals were kept under the care of a trained animal technician and cared for according to Canadian Council on Animal Care: Guide to the care and use of experimental animals [35].

Induction of Experimental Diabetes

Prior to diabetes induction, the rats were subjected to 12 hour fast and then diabetes was induced by intraperitoneal injection of 65mg/kg b.w [36] streptozotocin (STZ) (Sigma St. Louis, MO, USA) reconstituted in 0.1M Na citrate buffer (pH 4.5). Seven days after, diabetes was confirmed in STZ treated rats with a fasting blood sugar concentration ≥ 200mg/dl. The diabetic rats were then divided randomly into the different groups.

Experimental design and treatment of animals

36 male albino Wistar rats were divided into 6 groups of 6 rats each as shown in table 1. The plant extracts reconstituted in distilled water (vehicle) were administered via oral gastric intubation at a dose of 200mg/kg body weight daily for single extract treatment and 100mg/kg body weight each in combined extract treatment twice per day (7.00am and 7.00pm). Insulin (5IU/kg body weight) was administered subcutaneously once daily post prandial. The dosages of plant extracts extracts and insulin used were according to the methods of [37] and [38].Treatment lasted for 28 days.

Table 1 Experimental Design

Group	No. of animals	Treatment
A	6	Placebo (Diabetic Control)
B	6	GL extract (200mg/kg bw)
C	6	OG) extract (200mg/kg bw)
D	6	GL (100mg/kg) + OG (100mg/kg)
E	6	Insulin (5 IU/kg bw)
F	6	Placebo (normal control)

Preparation of serum

After 28 days of treatment, the animals were sacrificed by cervical dislocation.

The blood was collected through cardiac puncture using sterile needle to pierce through the heart and emptied into a strile test tube containing no anticoagulamt and was allowed to clot and centrifuged at 3000rpm at 4°C for 10 mins. The serum was used for the determination of alpha amylase.

Histopathology

After 28 days of treatment, the pancreas from each group was excised. It was immediately blotted using filter paper to remove traces of blood and then weighed with analytical balance. Thereafter, the tissue was suspended in 10% formalin after washing with normal saline for fixation preparatory to histological processing. Pancreas tissue was fixed in neutral formalin solution for 48 hrs dehydrated by passing through graded series of alcohol embedded in paraffin blocks. 4 µm thick sections were prepared using a semi-automated rotator microtome

Determination of serum alpha-amylase activity

This was determined using Agape diagnostic kit based on Junge et al. method [39].

Determination of blood glucose and organ weights

During this period, daily changes in blood glucose determined using One Touch Glucometer (with blood obtained from the tail vein of the rats). Internal organs such as liver, kidney, heart and pancreas were taken from all groups and weighed. Organ weights were measured and presented as organ per percentage weight (relative weight) Percentage weight change and relative organ weights calculations are shown below:

Percentage weight change= [Final body weight – Initial body weight/Initial body weight] X100

$$\text{Relative weight} = \frac{\text{Organ weight}}{\text{Final body weight}} \times \frac{100}{1}$$

3. Results and Discussion

In table 2, the effect of extracts of GL and OG singly and in combination and insulin on the percentage blood glucose change and serum α-amylase activity of diabetic rats produced striking changes. There were significant ($P< 0.05$) increase and decrease in blood glucose concentrations of diabetic control and diabetic treated rats respectively when compared to normal control. The diabetic treated rats showed reductions in blood glucose relative to DC rats. Combined extracts (GLOG) treated rats demonstrated significant ($P< 0.05$) decrease in blood glucose concentrations (by -84.10%) as compared to single GL (by -68.07%) and OG (by -65.37%) extracts treated rats.

Blood glucose levels of diabetic rats were monitored over the 28-day period. Glucose concentration measured in blood of untreated STZ-induced diabetic rats was significantly higher ($P<0.05$) than non-diabetic control. The observed increase in blood glucose has been reported [36, 38]. A sustained reduction in hyperglycemia will decrease the risk of developing micro vascular diseases and reduce their complications [40]. It has been established that lowering of the plasma glucose may be induced by the release of insulin, an endogenous peptide involved in the regulation of blood sugar [41]. In this study, this fact is strengthened by the significant ($p<0.05$) decrease in blood glucose in the diabetic rats treated with the extracts (so

pronounced in combined extracts) compared to untreated counterparts. This hypoglycemic effect could be attributed to the potentiation or stimulation of insulin production by the residual β-cells of the pancreas [42-45] or the extracts may possess an insulinomimetic effect on peripheral tissues [46] or both. The mechanism could be that *Gongronema latifolium* (GL) and *Ocimum gratissimum* (OG) decreased gluconeogenesis by decreasing the activities of key enzymes such as glucose-6-phosphatase, fructose-1,6- biphosphate- phosphoenolpyruvate carboxykinase and pyruvate carboxykinase [47]. The hypoglycemic activity and the blood glucose lowering activity elicited by these extracts singly and in combination explain the basis for the use of these leaves in the management of diabetes in traditional medicine practice. This observation gives credence to the use of these plant leaves as hypoglycemic agents.

Table 2. Blood Glucose level in blood and serum α-amylase activity of treated and untreated diabetic rats

Group/ treatment	Fasting Blood Glucose (mg/dL)			Serum α-Amylase (mg/dL)
	Initial	Final	% Change	
DC	367.50±2.33*	383.00±4.16*	3.86±0.53*	380.88±0.34*
D_{GL}	266.50±0.43*,a,b,c	85.33±1.91*,a,b,c	-68.07±0.78*,a,b	623.22±0.47*,a,b,c
D_{OG}	264.17±1.08*,a,b	89.17±0.31*,a,b	-65.37±1.07*,a,b	623.80±2.26*,a,b,c
D_{GLOG}	287.17±0.48*,a	45.67±0.61*,a	-84.10±0.22*,a	438.44±0.49*,a
D_I	266.67±3.50*,a,b	90.17±1.62*,a,b	-66.24±0.70*,a,b	405.54±2.15*,a,b
NC	44.83±0.31	41.83±0.17	-6.68±0.54	508.61±1.49

*p<0.05 vs NC; a = p<0.05 vs DC; b = p<0.05 vs D_{GLOG}; c = p<0.05 vs D_I
Values are expressed as mean ± SEM, n = 6.
DC= Diabetic control; D_{GL}= Diabetic treated with *Gongronema latifolium extract*
D_{OG} = Diabetic treated with *Ocimum gratissimum* extract;
D_{GLOG} = Diabetic treated with combined extracts of *Gongronema latifolium* and *Ocimum gratissimum* D_I= Diabetic treated with insulin; NC= Normal control

The activity of serum alpha amylase in diabetic untreated rats decreased (380.88± 0.34) significantly (P< 0.05) compared to NC (508.61± 1.49) rats. In diabetic GLOG extracts treated rats, its activity decreased (438.44±0.47) significantly (p<0.05) compared to single extract treated rats. In diabetic treated groups, the single extracts treatment demonstrated a significant increase in the activity of the enzyme when compared to normal control, combined extracts and insulin treated rats. Alpha-amylase is secreted by the pancreas into the duodenum where it aids the catabolism of carbohydrates to simple sugars. Damage to the pancreas or obstruction to the pancreatic duct causes the enzyme to enter the blood stream. It is most commonly relied on for detecting pancreatic disorder. The activity of this enzyme in serum of untreated diabetic rats decreased significantly compared to normal control. The decrease may not be

unrelated to the fact that STZ used in diabetes induction is more selective in attacking beta cells [48] and so may have spared the exocrine pancreas via minimal cross cell reaction. Also, the sustained hyperglycemia may also have over time exhausted the enzyme protein and its regulatory mechanism. In acute pancreatic disease where 75% of patients normally show significant serum increase in activity, the increase reaches its peak only in about 24 hours and returns to normal within 3-4 days [49]. The 28 day hyperglycemic duration would have imposed a decrease beyond normal values. The decrease and reversal of hyperglycemia following extracts administration necessitated the restoration of the exhaustion evidently shown by significant increase in the activity of the enzyme. This observation compared well with insulin treatment in diabetic animals.

The absolute and relative weights of the liver, kidney and heart of normal and diabetic (treated and untreated) rats are presented in table 3. The results showed significant increases in absolute and relative weights of diabetic control rats compared to normal control and treated rats. There were also decreases in absolute and relative weights of these organs in the diabetic extract treated groups compared to normal control rats. The combined GL and OG extracts treated diabetic animals exhibited decreases in these absolute and relative organ weights as compared to single GL and OG extract treated groups. There was significant ($P<0.05$) increase (0.41%) in the relative weight of diabetic control pancreas when compared to normal control (0.28%), extracts and insulin treated rats (figure 1). The combined extracts (GLOG) displayed a significant decrease (0.26%) in relative weight of the pancreas relative to single extracts (0.31%) treated rats.

Table 3. Final body weights and organ weights of treated and untreated diabetic rats

Group/ treatment	Final body weight (g)	Absolute organ weight (g)			Relative organ weight (%)		
		Liver	Kidney	Heart	Liver	Kidney	Heart
DC	199.17± 0.4*	10.63± 0.34*	1.74± 0.01*	0.92± 0.01*	5.34± 0.17*	0.87± 0.00*	0.46± 0.01*
D_{GL}	216.50± 1.15^{a,b,c}	9.89± 0.07^{a}	1.70± 0.00*^{,a,b,c}	0.90± 0.01*	4.57± 0.03^{a,b,c}	0.78± 0.00*^{,a,b,c}	0.42± 0.00*
D_{OG}	209.67± 2.01^{b,c}	9.97± 0.02^{a}	1.65± 0.02*^{,a,b,c}	0.82± 0.01*	4.76± 0.05^{a,b,c}	0.79± 0.01*^{,a,b,c}	0.39± 0.01*
D_{GLOG}	233.17 ±2.57*^{,a}	9.57± 0.02^{a}	1.56± 0.02^{a}	0.82± 0.01*	4.11± 0.04*,	0.67± 0.01*^{,a}	0.35± 0.01*
D_{I}	179.00± 3.73*^{,a,b}	9.57± 0.01^{a}	1.52± 0.01^{a}	0.82± 0.01*	5.36± 0.11*^{,b}	0.85± 0.02*,	0.46± 0.01*
NC	213.83±8.72	9.65±0.17	1.54±0.02	2.89±1.38	4.54±0.16	0.72±0.03	1.30±0.60

*$p<0.05$ vs NC; a = $p<0.05$ vs DC; b = $p<0.05$ vs D_{GLOG}; c = $p<0.05$ vs D_{I}

Values expressrd as are mean ± SEM, n = 6.

DC= Diabetic control; D_{GL}= Diabetic treated with *Gongronema latifolium extract*

D_{OG} = Diabetic treated with *Ocimum gratissimum* extract;

D_{GLOG} = Diabetic treated with combined extracts of *Gongronema latifolium* and *Ocimum gratissimum*, D_{I}= Diabetic treated with insulin; NC= Normal control

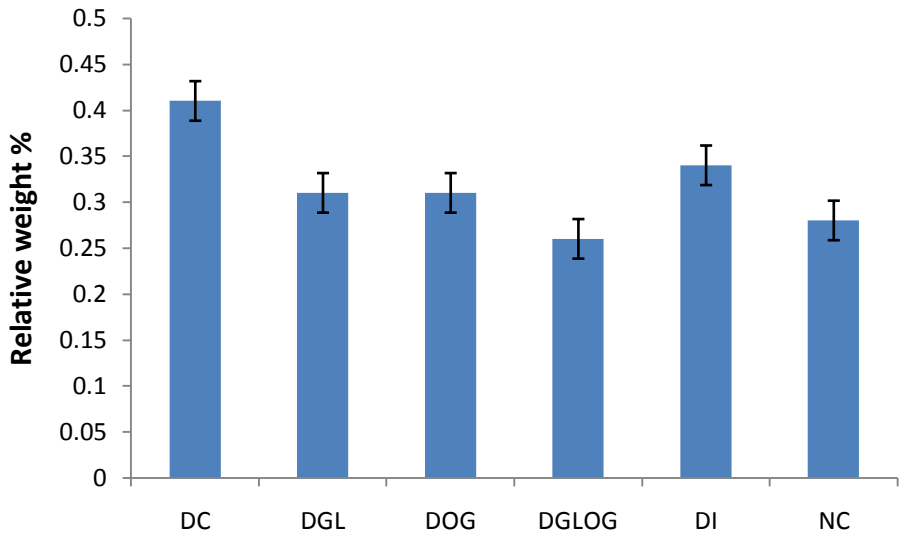

Figure 1. Relative weight of the pancreas of normal, and diabetic treated and untreated rats. The vertical bars show mean values of the relative weight of the pancreas. Lines above the bars indicate SEM.

Values expressed as are mean ± SEM, n = 6.
DC= Diabetic control; D_{GL}= Diabetic treated with *Gongronema latifolium extract*
D_{OG} = Diabetic treated with *Ocimum gratissimum* extract;
D_{GLOG} = Diabetic treated with combined extracts of *Gongronema latifolium* and *Ocimum Gratissimum* D_I=Diabetic treated with insulin; NC= Normal control

Measurement of anthropometric indices such as total body weight and weight changes of tissues are necessary because weight changes of these tissues are a useful measure of their pathological condition [50]. Analysis of organ weight in toxicology studies is an important endpoint for identification of potentially harmful effects of chemicals. Differences in organ weight between treatments groups are often accompanied by differences in body weight between these groups. Changes in body weight are a valuable indicator in evaluating the toxicity of a compound or extract preparation. It is known that as part of diabetes pathology, there is inhibition of normal body growth. Besides, the disease process is also known to involve enhanced utilization of body tissue proteins resulting in an appreciable degree of body wasting [51]. Our previous study revealed a pronounced significant ($P<0.05$) increase in body weights of rats treated with combined extracts compared to single [52]. This strongly suggests either the direct attenuation of tissue protein utilization of diabetes and / or reversal of inhibition of new tissue formation as a result of diabetes pathology. Moreover, The presence of antinutritional factors (phytic acids, tannins and oxalate) inhibit the activities of digestive enzymes and form complexes with metals (Ca, Zn, Mg, Fe) and proteins, reduce mineral and protein bioavailability [53,54]. This in turn may lead to low growth, notably reduced mean body weight. The liver, being a key organ in the metabolism and detoxification of xenobiotics, is vulnerable to damage induced by a huge variety of

chemicals. Thus, the observed significant increase in liver weight of untreated diabetic and group could be attributed to high rate of metabolism of the liver resulting from the exposure to STZ. The relative weights of pancreas increased significantly in diabetic control rats compared to treatment groups. Changes in weight of pancreas and beta cell mass of experimental subjects have also been used as indices to either monitor performance/efficacy of a treatment option or as a toxicity criterion and even physiological changes [55]. Furthermore, the decreases in absolute and relative weight of these organs of rats treated with the combined GL and OG (GLOG) extracts might be due to the synergistic effect of the anti-nutritional bioactive components (phytic acid and tannins) probably present in the plant extract.

The histology of pancreas of untreated normal pancreas (figure 2) showed normal pancreas cell architecture, preserved numerous islets- cell mass devoid of fibrosis. It showed islet cells of varying sizes distributed among the centroacinar cells. The pancreas of untreated diabetic rats (DC) revealed the presence of secretory acini and centroacinar cells, the lobules were distorted and the islet cells were necrotic and appeared degenerated (figure 3). Also seen is excretory duct containing amorphous eosinophilic material. Treatment with extracts of GL and OG alone (figure 4 and 5) and in combination (figure 6) reversed the observed pancreatic lesions. The combined extract treated rats displayed more pronounced positive effects showing normal pancreas cell architecture with features similar to normal control. The STZ-induced diabetic rats are suggestive of a model of uncontrolled hyperglycemia due to the direct pancreatic beta cell destruction and resulting insulin deficiency. Streptozotocin is known to induce chemical diabetics (type 1) by selective destruction of pancreatic beta cells through DNA alkylation, nitric oxide production and free radical generation [10]. Histopathological studies of the sections of pancreas revealed the disturbed morphological features in diabetic control rats. The untreated diabetic rats showing damaged islets markedly reduced and sunken mass agrees with reports in literature [56-58]. In this study pancreatic lesion resulting from this was reversed in STZ-induced diabetic treated rats after 28 days of treatment. The pancreatic lesions salvaging effects of extracts in combination (figure 6) were more potent than those treated with single extracts. Majority of plants have been reported to exert their hypoglycemic actions through the presence of insulin-like phytochemicals [59]. The potency of these substances may have amplified an account of increase concentration or build up of specific phytochemicals in combined extracts, although their chemistry is yet unknown. Our previous study had demonstrated the presence of phytochemicals with known antioxidant properties in the two leaves extracts [60]. The action of these phytochemicals might have arrested the free radical generation process or mop up the circulating radicals responsible for lesion and complications of diabetes, thereby allowing for regeneration of pancreatic islet cells. The reversal of pancreatic lesions observed in single extracts treatment compared well with the insulin (standard drug) treated group (figure 7) which showed mild islet cell hyperplasia with normal surrounding centroacinar cells.

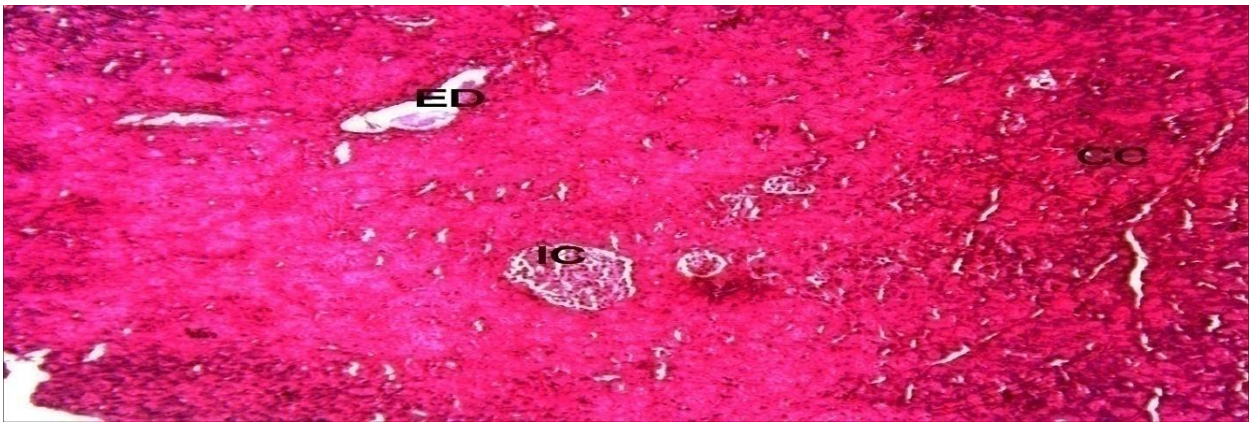

Figure 2. Photomicrograph of pancreas of (a) normal control rats given placebo treatment (x 400). IC= islet cell, ED= excretory duct, CC=centroacinar cells.

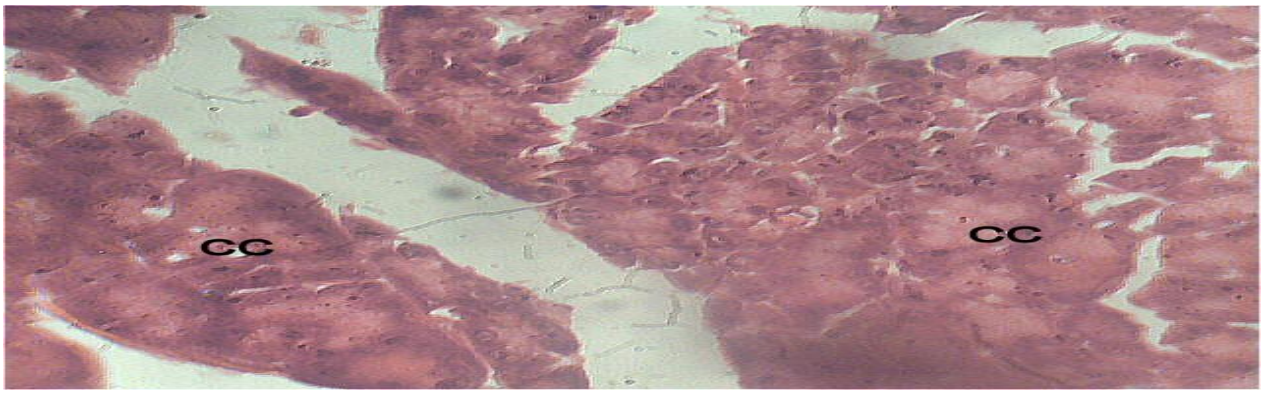

Figure 3. Photomicrograph of pancreas of diabetic control rats given placebo treatment (x 400). IC= islet cell, ED= excretory duct, CC=centroacinar cells.

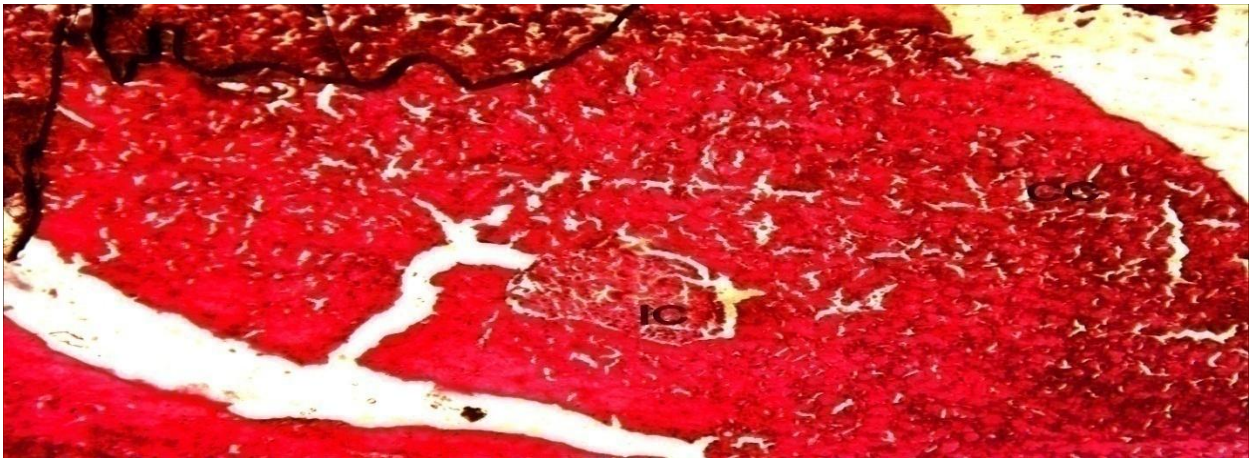

Figure 4. Photomicrograph of pancreas of diabetic rats treated with 200mg/kg b.w. of GL (x 400). IC= islet cell, ED= excretory duct, CC=centroacinar cells.

Figure 5. Photomicrograph of pancreas of diabetic rats treated with 200mg/kg b.w. of OG (x 400) IC= islet cell, ED= excretory duct, CC=centroacinar cells.

Figure 6. Photomicrograph of pancreas of diabetic rats treated with combined GL and OG x (100mg/kg b.w of each) (x 400) IC= islet cell, ED= excretory duct, CC=centroacinar cell

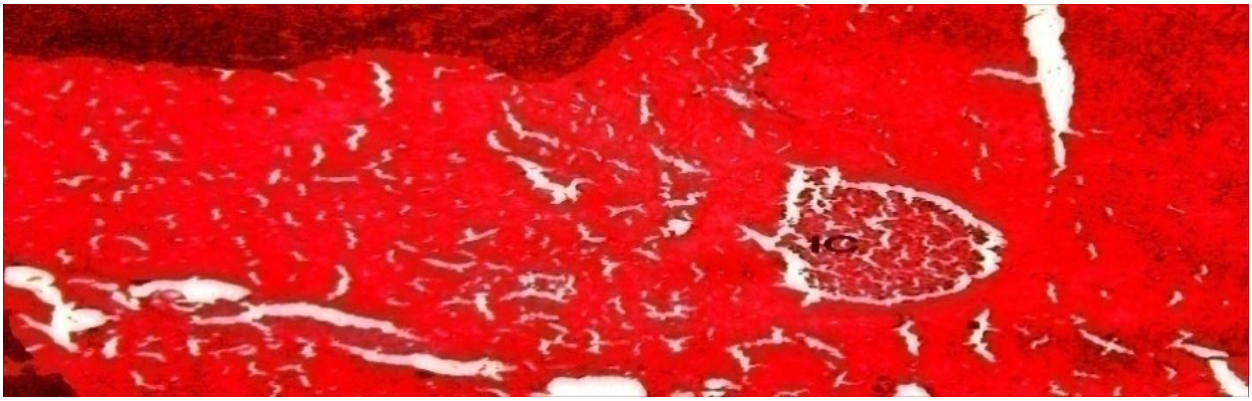

Figure 7. Photomicrograph of pancreas of diabetic rats treated with 5 IU/kg b.w. of Insulin (x 400). IC= islet cell, ED= excretory duct, CC=centroacinar cells.

Acknowledgements

The authors wish to acknowledge Prof Patrick Ebong, Prof (Mrs) H. Itam, Dr Friday Uboh all from the University of Calabar, and the financial assistance given by the Education Trust Fund, Federal Government of Nigeria.

References

1. Mahsud, MA J, Khan A, Hussain J. Hematological changes in tobacco using type 2 diabetic patients. Gomal. J Med Sci. 2010; 8:8-11.
2. King H, Aubert RE, Herman WH. Global burden of diabetes, 1995-2025: prevalence, numerical estimates, and projections. Diabetes Care, 1998; 21:1414-31.
3. Wild S, Roglic G, Green A, Sicree R, King H: Global prevalence of diabetes: estimates for the year 2000 and projections for 2030. Diabetes Care 2004, 27:1047–1053.
4. Mathis D, Vence L, Benoist C: Beta-Cell death during progression to diabetes. Nature 2001, 414:792–798.
5. Pitkänen OM, Martin JM, Hallman M, Åkerblom HK, Sariola H, Andersson SM. Free radical activity during development of insulin-dependent diabetes mellitus in the rat. Life Sci.; 1992, 50 (5):335–339.
6. Thulesen, J., Orskov, C., Hoist, J.J. & Paulsen, S.S. Short-term insulin treatment prevents the diabetogenic anction of streptozotocin in rats. Endocrinology, 1997, 138: 62-68.
7. Rodrigues, B., Poucheret, P., Betell, M.L. & Mc Neill, J.N.. Streptozotocin induced Diabetes: Induction, Mechanism(s), and Dose Dependency. In J. H. McNeill's (Ed.), Experimental Models of Diabetes, 1999, pp. 3-17.
8. Elsner, M., Guldkakke, B., Tiedge, M., Mu iday, R. & Lenzen, S. Relative importance of transport and alkylation for pancreatic bete-cell toxicity of streptozotocin. Diabetologia, 2000, 43: I528-I 533.
9. Turk, J., Corbett, J. A., Ramanadham, S., Bohrer, A. & Mcdaniel, M.L. Biochemical Evidence For Nitric Oxide formation from streptozotocin in isolated pancreatic islets. Biochemical, Biophysics Research Communications, 1993, 97: 1458-1464.
10. Szkudelski T. The mechanism of alloxan and streptozotocin action in B cells of the rat pancreas. Physiol. Res. 2001, 50(6): 537-46.
11. Larsen JL: Pancreas transplantation: indications and consequences. Endocr Rev 2004, 25:919–946.
12. Shapiro AM, Lakey JR, Ryan EA, Korbutt GS, Toth E, Warnock GL, Kneteman NM, Rajotte RV: Islet transplantation in seven patients with type 1 diabetes mellitus using a glucocorticoid free immunosuppre ssive regimen. N Eng J Med 2000, 343:230–238.
13. Ryan EA, Lakey JR, Rajotte RV, Korbutt GS, Kin T, Imes S, Rabinovitch A, Elliott JF, Bigam D, Kneteman NM, Warnock GL, Larsen I, Shapiro AM: Clinical outcomes and insulin secretion after islet transplantation with the Edmonton protocol. Diabetes 2001, 50:710–719.
14. Yamaoka T: Regeneration therapy of pancreatic beta cells: towards a cure for diabetes? Biochem Biophys Res Commun 2002, 296:1039–1043.
15. Gruessner, A.C. & Sutherland, D.E. Pancreas transplant outcomes for United States (US) and non-US cases as reported to United Network for Organ Sharing (UNOS) and the Internatio nal Pancreas Transplant Registry (IPTR). Clinical Transplantation, 2002, 41: 34-39.
16. Sutherland, D.E., Gruessner, A. & Herin, B.J. Beta-cell replacement therapy (pancrease and islet transplantation) for the treatment of Diabetes Mellitus: an integrated approach. Endocrinology and Metabolism, 2004, 33: 135-148.
17. Spellman, C.W. Islet cell dysfunction in progress to diabetes mellitus. Journal of

American Osteopathology Association, 2007, p. 36.
18. Meiver-Levy, I. & Ferber, S. New organs from our own tissues: Liver-to-pancrease transdifferentiation. Trends in Endocrino logy and Metabolism 2004, 14: 460-466.
19. Robertson, R.P. Pancreas transplantation for patients with Type 1 diabetes. Diabetes Care, 2004, 27 (1): 5105.
20. Matsumoto S, Noguchi H, Hatanaka N, Shimoda M, Kobayashi N, Jackson A, Onaca N, Naziruddin B, Levy MF: Estimation of donor usability for islet transplantation in the United States with the kyoto islet isolation method. Cell Transplant 2009, 18:549–556.
21. Yaro AH, Anuka JA, Salawu OA, Magaji MG. Anticonvulsant activities of methanol extract of Chrysanthellum indicum linn. Vatke in mice and chicks. Niger. J. Pharm. Sci., 2007, 6(2): 22-27
22. Risbud MV, Bhonde RR: Models of pancreatic regeneration in diabetes. Diab Res Clin Pract 2002, 58:155–165.
23. Vague P, Picq R, Bernal M, Lassmann-Vague V, Vialettes B: Effect of nicotinamide treatment on the residual insulin secretion in type 1 (insulin dependant) diabetic patients. Diabetologia 1989, 32:316–321.
24. Bolkent S, Yanardag R, Tabakoglu-Oguz A, Ozsoy-Sacan O: Effects of Chard extract (Beta vilgaris L. var. Cicla) extract on pancreatic beta-cells in streptozotocin–diabetic rats: a morphological and biochemical study.J Ethanopharmacol 2000, 73:251–259.
25. Xiu LM, Miura AB, Yamamoto K, Kobayashi T, Song QH, Kitamura H, Cyong JC: Pancreatic islet regeneration by ephedrine in mice with streptozotocin-induced diabetes. Am J Chin Med, 2001, 29:493–500.
26. Okafor, J.C. Identification and conservation of plants used in traditional medicine. Lead lecture presented at the international workshop on evaluation of traditional medicine. University of Nigeria, Nsukka, 1987.
27. Morebise, O., Fafunso, M.A., Makinde, J. M., Olayide, O. A. & Awe, E. Anti-inflammatory Property of Gongronema latifolium. Phytotherapy Research, 2002, 16: 575-577.
28. Farombi, E.O. African indigenous plants with chemotherapeutic potentials and sbiotechnological approach to the production of bio active prophylactic agents. African Journal of biotechnology, 2003, 2(12): 662-671.
29. Antai, A.B., Ofem, O.E., Ikpi, D.E., Ukafia, S. & Agiang, E. A phytochemistry and some haematological changes following oral administration of ethanolic root extract of gongronema latifolium in rats. Nigerian Journal of Physiological Sciences, 2009 24(1): 79–8.
30. Iweala, E.J. & Obidoa, O. Some biochemical, haematological and histological responses to a long term of a diet supplemented with leaves of Gongronema latifolium in male albino wistar rat. Journal of Biological Sciences, 2009, 9(8): 859-865.
31. Sulistiarini, D.L. Ocimum gratissimum L. In: Oyen PA, Nguyen ED (eds) Plant Resources of South-East Asia. No. 19: Essential oils Plants (Prosea Foundation, Bogor, Indonesia) 1999, p. 140
32. Sofowora, L.A. Medicinal plants and traditional medicine in Africa. Spectrum Books Ltd, Ibadan, Nigeria. Nigeria. 1993, p. 55.
33. Leal, P.F., Chaves, F., Celio, M., Ming, L.C., Petenate, A.J., Meireles, M. & Angela, A. Global yeilds, chemical composotions and antioxidant activities of Clove basil (Ocimum gratissimum L.). Journal of Food Processing Engineer. 2006, 29(5): 547-559.
34. Singh, A.P. Relevance of polyherbal formulations. 2005). (website:www. ayurvedia.com on June 09, 2008).
35. King J: The Hydrolases Acid and Alkaline Phosphatase. In Practical Clinical Enzymology. Edited by Van D. London: Nortstand Company Ltd; 1965:191-208.
36. Ugochukwu, N.H. & Babady, N.E. Antihyperglycemic effect of aqueous and

ethanolic extracts of Gongronema latifolium leaves on glucose and glycogen metabolism in livers of normal and streptozotocin-induced diabetic rats. Life Science, 2003, 73(15): 1925-1938.

37. Ebong, P.E. Atangwho. I.J., Eyong, E.U. Ukere, C. Obi, A.U. Pancreatic beta cell regeneration. A probable parallel mechanism of hypoglycaemic action of Vernomia amygdalina and Azadirachta indica. Proceedings of International Neem Conferencce, Kuming, China. 2006, Nov. 11-12.
38. Sonia, B. and Scrinivasan, B.P. (Investigations into the anti-diabetic activity of Azadirachia indica. Indian Journal of Pharmacology, 1999, 31: 138 - 141.
39. Junge, W., Troge, B., Klein, G., Poppe, W., Gerber, M. Evaluation of new assay for pancreatic amylase: Performance characteristics and estimation of reference intervals. Clinical Biochemistry, 1989, 22(2): 109-14.
40. Kim, J.S., Ju, J.B., Choi, C.W. & Kim, S.C. Hypoglycemic and antihypenlipidemic effect of four Korean medicinal plants in alloxan induced diabetic rats. American Journal of Biochemistry and Biotechnology, 2006, 2 (4): 154-160.
41. Cunha, W.R., Arantes, G.M., Ferreira, D.S., Lucarini, R., Silva, M.L.A., Furtado, A.A., Crotti, A.E.M. & Aruju, A.R.B. Hypoglycemiceffect of Leandra locunosa in normal and alloxan induced diabetic rats. Fitoterapia, 2008, 79: 356-360
42. Pari, L. & Maheswari, J.U. Hypoglycoemia effect of Musa sapientum (Linn) in alloxane- induced diabetic rats. Journal of Endoharmacology, 1999, 68: 321-325.
43. Eidi, A., Esmaeili, M. & Esmaeili, E. Antidiabetic effect of garlic (Allium sativum L.) in normal streptozotocin-induced diabetic rats. Phytomedicine, 2006, 13: 624-629.
44. Sharma, B., Viswanath, G.,Salunke, R. & Roy, P. Effect of flavoniod–rich Extracts from seed of Eugenia jambolana (L.) on carbonhydrate and lipid metabolism in diabetic mice. Food Chemistry, 2008, 110: 697-705.
45. Djomeni, P.D.D., Tedong, L., Asongalem, E.A., Dimo, T., Siokena, S.D. & Kamtchouring, P. Hypoglycaemia and Antidiabetic effect of root extract of Ceiba pentandra in normal and diabetic rats. African Journal of Traditional Comp and Alternative Medicine, 2006, 3(1): 129-136.
46. Murray, R.R., Granner, D.K., Mayes, P.A. & Roywell, V.W. Harper Biochemistry, 25th Edition. Stamford Connecticuti Appleton and Lange, 2000, 610-617.
47. Rodrigues, B., Poucheret, P., Betell, M.L. & Mc Neill, J.N. Streptozotocin induced Diabetes: Induction, Mechanism(s), and Dose Dependency. In J. H. McNeill's (Ed.), Experimental Models of Diabetes, 1999, pp. 3-17.
48. Leob, S. (Ed). Clinical laboratory Test: Values and Implicationns, Copyright edtion. Pennsylvania: Springhouse Corporation, Springhouse. 1991, pp. 498-500.
49. Dunchen, L.W., Corselline, J.A. & Adams, J.H. Green fields neuropathology, 4th edn. London, Edward Anold. 1984.
50. Gale, E.A.M. & Anderson, J.V., Diabetes Mellitus and other disorders of metabolism. In P. Kumas and M. Clark (eds.). Clini. Med. 4th Ed. W.B. Sunders, London, 1999 pp. 959- 1006.
51. Usoh, I. F. Akpan, H. D. Ekaidem, I.S., Uboh, F. E. Luke, U. O. Changes in blood glucose, body weights and serum lipids of streptozotocin-induced diabetic rats treated with combined leaf extracts of Gongronema latifolium and Ocimum gratissimum. European journal of Scientific Research 2015, 130(1): 68-81
52. Eleyinmi, A., Adebowale, Y., Oluwalana, I., Ajisafe, O. & Akintomide, T. Effect of Dietary Inclusion of Garcinia kola, Gongronema latifolium and Vernonia amygdalina on the Nutritional Quality of a Complementary Diet. Journal of Biological Sciences, 2006. 1: 43-49.
53. Eleyinmi, A., Sporns, P., Bressler, D., Nutritional Composition of Gongronema

latifolium and Vernonia amygdalina. Journal of Nutrition and Food Science, 2008, 38: 99-109

54. Svensson, A. M., Ostenson, C. & Janssson, L. Age-induced Changes in Pancreatic Islet blood flow: Evidence for an impaired regulation in diabetes GK rats. American Journal Endocrinology and Metabolism, 2000, 279: 1139-1144.
55. Bolkent S, Yanardag R, Tabakoglu-Oguz A, Ozsoy-Sacan O: Effects of Chard extract (Beta vilgaris L. var. Cicla) extract on pancreatic beta-cells in streptozotocin–diabetic rats: a morphological and biochemical study. J Ethanopharmacol 2000, 73:251–259.
56. Jelodar, G., Mohsen, M. & Shahram, S. Effect of walnut leaf, coriander and pomegranate on blood glucose and histopathology of pancreas of alloxan induced diabetic rats. African Journal of Traditional, complementary and A item alive Medicines, 2007, 4(3): 299-3 05.
57. Noor, A., Gunasekeran, S., Manicckam, A. S. & Vijayaiakshmi, M. A. Antidiabetic activity of Aleo vera and histology of organs in streptozotocin-induced diabetic rats. Current Science, 2008, 94(8): 1070-1076.
58. Yeh, G. Y., Eisenberg, D.M., Kaptcul, T.J and Philips R.S. Systemic review of herbs and dietary supplements for glycemic control in diabetes. Diabetes Care. 2003, 26 (4), 1277-1294.
59. Usoh, I. F., Akpan, H. D. and Akpanyung, E. O., Combined Phytochemicals from Gongronema latifolium and Ocimum gratissimum Leaves Extracts Potentiate in vitro Free Radical Scavenging. IOSR International Journal of Pharmacy and Biological Sciences 2015, 10(5):68-74.